



Minimally Invasive Approach for Mid-Esophageal and A Giant Epiphrenic Diverticula: Case Report

Orta Özofagial ve Dev Epifrenik Divertikülde Minimal İnvazif Yaklaşım: Olgu Sunumu

Giant Epiphrenic Diverticula

Muharrem Ozkaya¹, Mehmet Ozdogan², Sefa Ozyazici², Koray Das², Safa Onel²
¹Department of Thoracic Surgery, Antalya Training And Research Hospital, Antalya,
²Department of Thoracic Surgery, Adana Numune Training And Research Hospital, Adana, Turkey

Presented at the 18th National Surgical Congress¹², 23-27 May 2012

Özet

Özofagus divertikülleri nadir olup bu hastaların yönetimi tartışmalıdır. Bu çalışmada orta Özofagus ve dev epifrenik divertikülü olan iki hastada minimal invazif yaklaşımla ilgili başlangıç deneyimlerimizi bildirdik. Orta özofageal divertikül olan bir hastaya özofagoskop eşliğinde torakoskopik divertikülektomi yaptık. Diğer geniş epifrenik divertikülü olan hasta ise kombine torakoskopik divertikülektomi ve laparoskopik özofajektomi ve funduplikasyon ile tedavi edildi. Torakoskopik divertikülektomi güvenli ve etkin bir ameliyattır. İntraoperatif endoskopi ile kombine edildiğinde torakoskopik işlemin etkinliği artmaktadır.

Anahtar Kelimeler

Torakoskopik Cerrahi; Özofagus Divertikülü; Özofagoskopi

Abstract

Esophageal diverticula are rare entities. We report our initial experience with a minimally invasive approach to mid-esophageal and epiphrenic diverticula in two cases. One patient with mid-esophageal diverticula was treated with esophagoscopy-guided thoracoscopic diverticulectomy. The other patient, with a large epiphrenic diverticulum, was treated with combined thoracoscopic diverticulectomy and laparoscopic esophagomyotomy and fundoplication. Thoracoscopic diverticulectomy is a safe and effective operation. When combined with intraoperative endoscopy, this approach further increases the efficiency of the thoracoscopic procedure.

Keywords

Thoracoscopic Surgery; Esophageal Diverticulum; Esophagoscopy

DOI: 10.4328/JCAM.4173

Received: 02.12.2015 Accepted: 22.12.2015 Printed: 01.03.2016

J Clin Anal Med 2016;7(2): 268-70

Corresponding Author: Muharrem Ozkaya, Department of Thoracic Surgery, Antalya Training And Research Hospital, Soğuksu 07100 Antalya, Türkiye.

GSM: +905326543438 F.: +90 2422494462 E-Mail: drmuharremozkaya@gmail.com

Introduction

Esophageal diverticula are rare entities that affect an estimated 0.02% to 0.77% of people, most of whom are asymptomatic [1]. Mid-esophageal diverticula are usually traction diverticula that occur secondary to mediastinal inflammation. On the other hand, epiphrenic diverticula are pulsion type and occur as a mucosal pouch protruding through the muscularis wall. Epiphrenic diverticula are frequently associated with achalasia, followed by diffuse esophageal spasm [2,3].

Traditionally, thoracotomy has been the preferred surgical approach. Recently, minimally invasive approaches have been reported in a few series. However, the best surgical approach remains uncertain [4].

In this article, we present our initial experience with a minimally invasive approach to manage a mid-esophageal and an epiphrenic diverticulum in two cases. One patient with a mid-esophageal diverticulum was treated with an esophagoscopy-guided thoracoscopic diverticulectomy. The other patient, with a large epiphrenic diverticulum, was treated with combined thoracoscopic diverticulectomy and laparoscopic esophagomyotomy and partial fundoplication.

Case Report

Patient 1

A 63-year-old man was admitted to our hospital with the complaints of regurgitation and nocturnal cough. A barium swallow radiographic examination revealed an outpouching arising from the right lateral wall of the mid-esophagus (Figure.1). The gas-

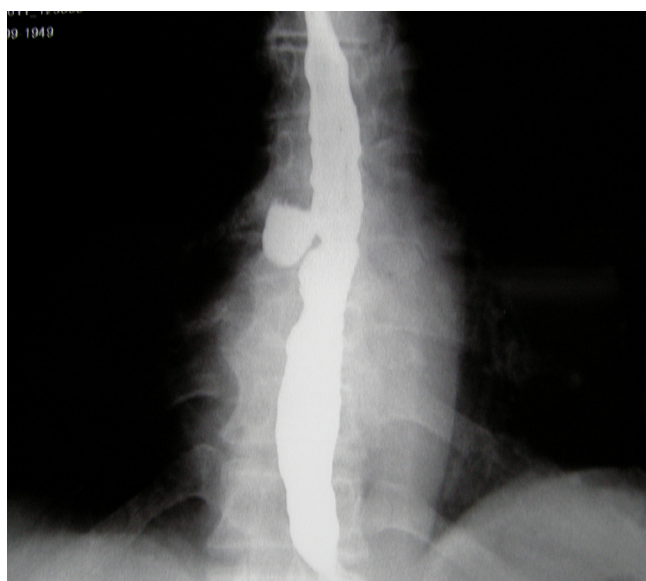


Figure 1. Barium swallow of thoracic diverticulum

tro-esophageal junction was in the normal anatomical position. No evidence of achalasia was present. Endoscopic images of the esophagus revealed an esophageal diverticulum visualized as an invagination to the right of the lumen located at 31 cm from incisors (Figure.2A).

After preoperative evaluation, the patient was scheduled for a thoracoscopic resection. Selective left intubation under general anesthesia was performed, and the right lung was completely collapsed immediately after the patient was positioned in a left lateral position as for an ordinary right posterolateral thoracotomy.

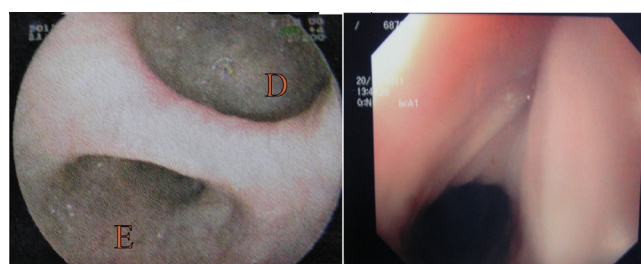


Figure 2. Endoscopic view of thoracic diverticulum. D: Diverticulum; E: Esophageal lumen (A), Perioperative endoscopic view of esophageal lumen following application of endo-GIA before firing(B).

A 10 mm trocar was inserted from the 7th intercostal space in the mid-axillary line for the camera. After inspection of the thoracic cavity, the other three trocars, one from the 5th intercostal space at the anterior axillary line (10 mm), and two through the 9th intercostal spaces at the posterior and mid-axillary line (5 mm each), were inserted. Although the esophagus was dissected up to the azygous vein, we were unable to identify the diverticulum clearly. Therefore, the diverticulum was transilluminated using an intraoperative esophagoscope, positively identified, and dissected consecutively.

The incision at the 9th intercostal spaces at the posterior axillary line was expanded for a 12 mm trocar. An Endo-GIA 60 mm roticulator stapler (AutoSuture®, United States Surgical, Norwalk, CT, USA) was then introduced through this trocar and was applied to the neck of the diverticulum along the longitudinal axis of the esophagus. The lumen size of the esophagus and the exact position of the stapler were assessed by esophagoscope before firing (Figure.2B).

The staple line was evaluated by air insufflation through the esophagoscope. A no:32 F thorax drain was inserted through the antero-inferior port incision. No nasogastric drain was placed. The operating time was 100 minutes; blood loss was insignificant. The thorax drain was removed on postoperative day 3. Liquids were commenced on the second postoperative day, followed by a soft diet on the following day. The patient was discharged on postoperative day 7.

Patient 2

A 62-year-old female patient was admitted to our hospital with complaints of dysphagia and regurgitation of food particles soon after eating. A barium swallow revealed a diverticulum measuring 3x5x5 cm in the lower esophagus, just above the gastroesophageal junction. Upper gastrointestinal endoscopy confirmed the presence of a large diverticulum extending from the esophageal lumen. After preoperative evaluation, the patient underwent a thoracoscopic diverticulectomy as described for patient 1, and then laparoscopic esophagomyotomy and Toupet fundoplication were performed.

Discussion:

Esophageal diverticula are rare, with a prevalence of 0.06% to 4% based on radiologic and endoscopic series [5]. Most of the patients with esophageal diverticula are asymptomatic. Dysphagia is the most common symptom, but regurgitation, weight loss, chest pain, halitosis, and aspiration are also common complaints.

The management of these patients is still controversial. According to some authors, for asymptomatic patients with small

diverticula (5 cm), routine clinical and esophagoscopy follow-up is advised; surgical therapy is typically reserved for large symptomatic diverticula [6]. On the other hand, because of the prevalence of aspiration (45%) and the potential for life-threatening pulmonary complications (15%), operative intervention should be undertaken in all patients with thoracic esophageal diverticula regardless of the presence or absence of symptoms [7].

Surgical therapy has traditionally been performed through a thoracotomy. Recent advances in minimal access surgery have led to thoracoscopic and laparoscopic management of this disease. In a recent comprehensive study of 133 esophageal epiphrenic diverticula, nineteen patients (14 %) underwent thoracoscopic surgery, 112 (84 %) laparoscopic surgery, and two patients (2 %) were treated using a combination approach [4]. Our first patient underwent thoracoscopic surgery and our second patient was treated with a combined approach. Also in our first patient, by using peroperative endoscopy, we were able to accurately localize the diverticula and determine the level of stapler application safely.

Conclusion: Thoracoscopic diverticulectomy is a safe and effective operation. When combined with intraoperative endoscopy, this approach further increases the efficiency of the thoracoscopic procedure.

Competing interests

The authors declare that they have no competing interests.

References

1. Thomas ML, Anthony AA, Fosh BG, Finch JG, Maddern GJ. Esophageal diverticula. *Br J Surg* 2001;88:629-42.
2. Tedesco P, Fisichella PM, Way LW, Patti MG. Cause and treatment of epiphrenic diverticula. *Am J Surg* 2005;190:891-4.
3. Melman L, Quinlan J, Robertson B, Brunt LM, Halpin VJ, Eagon JC, et al. Esophageal manometric characteristics and outcomes for laparoscopic esophageal diverticulectomy, myotomy, and partial fundoplication for epiphrenic diverticula. *Surg Endosc* 2009;23:1337-41.
4. Hirano Y, Takeuchi H, Oyama T, Saikawa Y, Niihara M, Sako H, et al. Minimally invasive surgery for esophageal epiphrenic diverticulum: the results of 133 patients in 25 published series and our experience. *Surg Today* 2013;43(1):1-7.
5. Hoghooghi D, Coakley FV, Breiman RS, Qayyum A, Yeh BM. Frequency and etiology of midesophageal diverticula at barium esophagography. *Clin Imaging* 2006;30:245-7.
6. Zaninotto G, Portale G, Costantini M, Merigliano S, Guirroli E, Rizetto C, et al. Long-term outcome of operated and unoperated epiphrenic diverticula. *J Gastrointest Surg* 2008;12:1485-90.
7. Altorki NK, Sunagawa M, Skinner DB. Thoracic esophageal diverticula. Why is operation necessary? *J Thorac Cardiovasc Surg* 1993;105:260-4.

How to cite this article:

Ozkaya M, Ozdogan M, Ozyazici S, Das K, Onel S. Minimally Invasive Approach for Mid-Esophageal and A Giant Epiphrenic Diverticula: Case Report. *J Clin Anal Med* 2016;7(2): 268-70.